The book cover features a collage of images related to venomous Australian fauna. In the top left, a green spider web is visible against a dark background. Below it, a large, detailed image of a brown and black snake (likely a tiger snake) is the central focus. To the left of the snake, a black and white spider is shown on a piece of wood. Above the snake, a purple jellyfish is depicted. To the right of the snake, there is a close-up of a colorful, textured surface, possibly a coral or a piece of wood covered in lichen. The background is a mix of dark and light colors, with a large, glowing orange and yellow sphere in the upper right.

A Clinician's Guide to Australian Venomous Bites and Stings

Incorporating the updated CSL Antivenom Handbook

Principal author
Associate Professor Julian White

The opinions expressed are not necessarily those of bioCSL Pty Ltd. Before administering or prescribing any prescription product mentioned in this publication please refer to the relevant Product Information. Product Information leaflets for bioCSL's antivenoms are available at www.biocsl.com.au/PI.

This handbook is not for sale.

Date of preparation: February 2013.

National Library of Australia Cataloguing-in-Publication entry.

Author: White, Julian.
Title: A clinician's guide to Australian venomous bites and stings: incorporating the updated CSL antivenom handbook / Professor Julian White.
ISBN: 9780646579986 (pbk.)
Subjects: Bites and stings – Australia.
Antivenins.
Bites and stings – Treatment – Australia.
Other Authors/
Contributors: CSL Limited (Australia).
Dewey Number: 615.942

Medical writing and project management services for this handbook provided by Dr Nalini Swaminathan, Nalini Ink Pty Ltd; +61 416 560 258; nalini@iinet.net.au. Design by Spaghetti Arts; +61 410 357 140; spaghettiarts@gmail.com.

© Copyright 2013 bioCSL Pty Ltd, ABN 26 160 735 035; 63 Poplar Road, Parkville, Victoria 3052 Australia. bioCSL is a trademark of CSL Limited. bioCSL understands that clinicians may need to reproduce forms and flowcharts in this handbook for the clinical management of cases of envenoming and permits such reproduction for these purposes. However, except for the purpose of clinical management of cases of envenoming from bites/stings from Australian venomous fauna, no part of this publication may be reproduced by any process in any language without the prior written consent of bioCSL Pty Ltd.

Where applicable, copyright of photos, illustrations and flowcharts included in this handbook that have been reproduced with permission, is attributed to the appropriate person/authority. Maps regarding the distribution of various venomous fauna in Australia obtained courtesy A/Prof Julian White. Cover photos: Box jellyfish photo copyright Dr Lisa-ann Gershwin, Australian Marine Stinger Advisory Services; all other cover photos copyright bioCSL Pty Ltd.

Editorial content: Although great care has been taken in compiling and checking the information provided in this publication to ensure that it is accurate, bioCSL Pty Ltd shall not be responsible for the continued currency of the information, or for any errors, omissions or inaccuracies in this publication.

Section 4

Spiders

- Background
- Spiderbite: Clinical presentation
- Spiderbite: First aid
- Spiderbite: Diagnosis
- Management of envenoming due to spiderbite
- Antivenom therapy
- Necrotic arachnidism

In this section

176

Spiderbite: Background

Overview 177

Spiderbite: Clinical presentation

Local signs/symptoms 178
General systemic effects 178
Specific systemic effects 179
Spiderbite in children 179
Problem presentations 180
Specific presentations 181
Funnel web spider bite 182
Red back spider bite 183

Spiderbite: First aid

General principles 184
Funnel web spider bite: Timing of removal of PBI first aid 184

Spiderbite: Diagnosis

Principles of diagnosis and management 186
Spiderbite: Observation 187
History 188
Examination 189
Laboratory investigations 189
Key symptoms/signs of envenoming based on spider species 190
Diagnostic algorithms 191

Spiderbite decision tree based on clinical presentation (flowchart) 192

Spider identification

Identifying a spider 193

Management of envenoming due to spiderbite

Basic principles 195
Urgent treatment 196
Management of suspected or confirmed funnel web spider bite (flowchart) 197
Management of suspected or confirmed red back spider bite (flowchart) 198

Specific treatment for funnel web spider bite: Antivenom

Indications for antivenom therapy 199
Timing of antivenom therapy 199
Initial dose of bioCSL's Funnel Web Spider Antivenom 200
Follow-up dosing: bioCSL's Funnel Web Spider Antivenom 200

Route of administration of bioCSL's Funnel Web Spider Antivenom 201
Monitoring patients after antivenom therapy 201
What if bioCSL's Funnel Web Spider Antivenom is not immediately available? 202

Specific treatment for red back spider bite: Antivenom

Envenoming from red back spider bite 203
Indications for bioCSL's Red Back Spider Antivenom 203
Timing of bioCSL's Red Back Spider Antivenom therapy 203
Dose of bioCSL's Red Back Spider Antivenom 204
Route of administration of bioCSL's Red Back Spider Antivenom 205
What if bioCSL's Red Back Spider Antivenom is not immediately available? 206

Spider antivenoms: Preparation, administration and complications

Preparation prior to commencing antivenom therapy 207
How to administer spider antivenoms:
 bioCSL's Funnel Web Spider Antivenom 208
 bioCSL's Red Back Spider Antivenom 209
Observation during antivenom therapy 210
Premedication prior to administering antivenom 211
What to do if there is an adverse reaction to antivenom 213
Antivenom therapy: Commonest mistakes 214
Complications of antivenom therapy 215
Management of serum sickness 216

Necrotic arachnidism

Necrotic arachnidism: Evidence *versus* mythology 217
Necrotic skin lesions: Approach to investigations (flowchart) 220

Australian spiders overview

Funnel web spider group 221
Red back spiders 223
Mouse spiders 226
Other spiders 227

Spiderbite: Background

Overview

- Australia is home to a vast array of spider species, most of which are small and unlikely to bite or cause significant effects in humans.^{1,2}
- Clinical effect profiles have been described for bites by only a limited number of spider species.¹⁻³
- For the majority of reported symptomatic spider bites, the predominant feature is local pain, usually of short duration.^{2,3}
- A few species can cause significant envenoming, either local or systemic, and one group, the **funnel web spider group, can cause potentially lethal envenoming in humans.**^{4,6}
 - Consequently, the funnel web spider group drives the diagnostic process for spiderbite. It is essential to rapidly assess and treat any bite by a spider that may be a funnel web species.⁶
 - Unfortunately, confounding the diagnostic process for the funnel web spider group are a significant number of similar looking spiders that are broadly grouped as 'big black spiders'.^{6,7}
- A second group of medical significance includes the red back spiders. While unlikely to cause lethal envenoming, bites from these spiders can result in effects, which frequently require medical treatment.^{3,4}
- To assist in appropriate triage and management of patients with spiderbite a diagnostic algorithm has been developed based on clinical presentation (see page 192).⁸

The funnel web spider group drives the diagnostic process for spiderbite. It is essential to rapidly assess and treat any bite by a spider that may be a funnel web species

Spiderbite: Clinical presentation

Presenting symptoms following spiderbite can be highly variable, depending on the type of spider involved. Importantly, bites from some medically important spiders can cause a fairly specific and diagnostic set of symptoms.^{2,7}

Local signs/symptoms^{2,7,9,10-13}

- No symptoms to minor swelling; erythema.
- Bites may be painless through to exquisitely painful with pain being either immediate or delayed.
- Bite marks are frequently invisible, but larger species (e.g. funnel web spiders/ big black spiders, and huntsman spiders) can cause obvious punctures, occasionally with local short-lived bleeding.
- Lymph nodes draining the bite area may sometimes be swollen and/or tender, indicating venom movement.
- ‘Necrotic arachnidism’, i.e. skin damage/ulceration/necrosis caused by suspected spiderbite, is generally an inappropriate diagnosis in Australia as evidence supporting the association between spider bites in Australia and skin necrosis, is lacking^{2,12,13} (see pages 217-220 for further explanation).

General systemic effects^{2,3,4,9}

- Non-specific general systemic effects following spiderbite are uncommon.
- Symptoms may include nausea/vomiting, headache, abdominal pain.



Sydney funnel web spider (male), *Atrax robustus*.



Fangs of Sydney funnel web spider *A. robustus*.



Red back spider (female), *Latrodectus hasseltii*.

Photos of the male Sydney funnel web spider (*A. robustus*) and red back spider copyright A/Prof Julian White. Photo of *A. robustus* fangs copyright Museum of Victoria.

Specific systemic effects

Envenoming from spiderbite can lead to a number of specific systemic effects with varied presentations (Table 24).

Table 24. Specific systemic effects of spider venoms: Presenting signs/symptoms^{4,8,9,14}

Systemic effect of spiderbite	Presentation
Neuroexcitatory envenoming	<ul style="list-style-type: none">– Hypertension/hypotension– Tachycardia/bradycardia– Piloerection– Increased sweating– Hypersalivation/lacrimation– Muscle spasm/pain– Respiratory distress/pulmonary oedema– Muscle fasciculation– Severe abdominal or chest pain
Systemic myolysis	In general does not occur, although rare cases of envenoming from red back spider bite can be associated with a mild rise in CK
Coagulopathy	Does not occur* (except in rare cases as a secondary complication)
Renal damage	Does not occur* (except in rare cases as a secondary complication)

*Important diagnostic feature.

Spiderbite in children^{3,8,9,10,14}

In children, especially young children, spiderbite can lead to more severe and rapidly developing envenoming (funnel web spiders; red back spiders). Young children may present with any of above symptoms but without a clear history of spiderbite, necessitating a high index of suspicion for accurate diagnosis.

Spiderbite: Clinical presentation

Problem presentations

- Generally, in adults, problem/cryptic presentations of spiderbite are of lesser relevance to clinical practice (than for snakebite).
- This is primarily because clinical experience suggests that spiderbite may be overdiagnosed given the tendency in the general community to associate any sort of localised skin reaction with spiderbite, and in particular, the inappropriate association between skin damage and the white tail spider.^{2,3,8,12,13}

Many cases of alleged spiderbite may not be associated with a witnessed bite – resulting in a speculative diagnosis of spiderbite.⁸

On the other hand, the most important spiderbite, i.e. that from funnel web spiders, is mostly associated with a clear episode of a bite being felt and a spider seen.^{2,6}
- Red back spider bite, though commonly presenting without a clearly witnessed bite, frequently presents with clear symptoms and signs pointing to a diagnosis.^{8,9}

The patient may present with abdominal or chest pain in the absence of a noticed bite.^{4,8,9}

In such cases, careful questioning usually will elicit a history of possible exposure to spiderbite and initial localised pain, indicating the true diagnosis.^{4,8}
- Consequently, unlike snakebite, medically significant spiderbite will present with clear symptomatology in most cases.⁸

Unlike snakebite, medically significant spiderbite will present with clear symptomatology in most cases

Specific presentations

Funnel web spider group

- Funnel web spiders only occur naturally in parts of eastern and southeastern Australia (see map on page 221).^{5,7,14,15} Bites by the numerous species within this group are potentially rapidly lethal. The bites are often painful and a bite mark is usually seen.^{7,9,14}
- Medically significant bites have thus far been confined to eastern NSW and southeast QLD.^{9,14}
- Bites by a variety of related spiders (big black spiders) may be confused with those of true funnel web spiders.⁷
- However, the majority of funnel web spider bites will prove to be minor and will not lead to systemic envenoming.^{7,9}

Table 25 (page 182) depicts features relating to systemic envenoming from funnel web spider bite.

Mouse spiders

- Mouse spiders of the genus *Missulena* have venom similar to funnel web spiders and potentially can cause a similar envenoming syndrome.^{7,16}
- However, clinical experience indicates that bites are uncommon and significant envenoming occurs very rarely.^{2,16}

Red back spider group

- Red back spiders are part of the widow spider group (genus *Latrodectus*).
- These spiders are common as well as a common cause of bites.^{2,3}
- The bite site may be painless or it may feel like a pinprick.¹⁰
- In one study, the majority of definite red back spider bites caused significant effects including severe persistent pain in two-thirds of cases.⁴
- While often distressing for the patient, red back spider envenoming is not likely to be lethal.³ There have been no reports of death from a red back spider bite since the introduction of antivenom.⁹
- Clinical features of systemic envenoming due to red back spider bite are shown in Table 26 on page 183.

Spiderbite: Clinical presentation

Funnel web spider bite

Table 25. Funnel web spider bite: Clinical presentation^{3,7-9,14}

Bite and bite site	<ul style="list-style-type: none"> – The bite itself is painful – Usually, fang marks are obvious – The spider may remain attached to the patient until shaken off or otherwise removed
Timing of development of systemic envenoming	<ul style="list-style-type: none"> – Where systemic envenoming develops, it will do so within 4 hours of the bite¹⁴ – Initial symptoms may develop as early as 10-15 min post bite
Systemic envenoming symptoms	<ul style="list-style-type: none"> – Earlier symptoms are perioral tingling with or without tongue fasciculation – Headache, nausea, vomiting and abdominal pain may all occur – Autonomic excitation causes increased sweating, salivation and lacrimation, and piloerection – The patient initially is hypertensive and tachycardic, although bradycardia and later hypotension is sometimes observed – There may be rapid progression to pulmonary oedema and consequent dyspnoea and cyanosis. Resultant hypoxia may produce irritability, decreased consciousness, or even coma
Diagnostic tests	<ul style="list-style-type: none"> – None available

Red back spider bite

Table 26. Red back spider bite: Clinical presentation^{4,8-10,17,18}

Bite and bite site	<ul style="list-style-type: none"> – The majority of patients will feel the bite, but perhaps only as a pinprick. In some cases, the bite may be painless – Local sweating at the bite site is common. Sometimes local erythema or blanching, or piloerection may occur
Timing of development and symptoms of systemic envenoming	<ul style="list-style-type: none"> – Within minutes to an hour or more after the bite, significant local pain develops around the bite area, often with increased sweating – Over the following hours, the pain may become more severe and spread proximally, often with pain and/or swelling of the draining lymph nodes. As the pain spreads proximally it may lessen in the bite area – Sweating may become regionalised and the patient may develop nausea, become hypertensive, and suffer general malaise – In more severe cases generalised symptoms may develop, involving most or all of the body, and the pain may mimic acute abdomen or cardiac chest pain – If left untreated, this pain syndrome may last hours to days
Classic presentations	<ul style="list-style-type: none"> – A triad of progressive severe pain, marked sweating and hypertension – A triad of local bite site pain, sweating and piloerection¹⁷ – Gravitation of symptoms to the lower limbs in delayed presentations – i.e. burning sensation in the soles of the feet and pain and profuse sweating of both lower legs even if the bite was elsewhere
Diagnostic tests	<ul style="list-style-type: none"> – None available

Spiderbite: First aid

General principles^{9,19}

- The majority of spider bites do not require specific first aid.
- Pressure Bandaging & Immobilisation (PBI) first aid should be applied for bites by funnel web spiders and related big black spiders (see pages 38-43 in Section 2 for details of PBI application).¹⁹
- Red back spider bites do not require specific first aid other than perhaps intermittent application of ice or a cold compress. The PBI technique is contraindicated as it may worsen pain.¹⁹

PBI first aid should be applied for bites by funnel web spiders... [but the] PBI technique is contraindicated for red back spider bite as it may worsen pain

184

Funnel web spider bite: Timing of removal of PBI first aid^{5,8}

In patients bitten by funnel web spider, the removal of first aid may precipitate severe systemic envenoming.

Consequently, for cases of suspected funnel web spider bite or bite by any other big black spider, first aid measures **should not be removed** until the patient has been admitted to an intensive care unit or emergency department that holds bioCSL's Funnel Web Spider Antivenom and has access to resuscitation facilities and skilled clinicians.

When patients bitten by funnel web spider/other big black spider present to an appropriately resourced medical facility, a number of steps must be undertaken prior to the removal of PBI first aid (see Table 27 on page 185).

Table 27. Timing and process of PBI first aid removal for funnel web spider bite^{3,5,7-9,14}

Key principle	Funnel web spider bite should be managed as a medical emergency
Removal of PBI first aid in funnel web spider bite: General principles	<p>Patient must be stable – if the patient is unwell, or exhibits unstable observations or is obviously envenomed, do not remove PBI first aid</p> <p>If the patient does not show signs of envenoming at presentation, PBI first aid should be removed only if Funnel Web Spider Antivenom is immediately available along with a clinician experienced in resuscitation</p>
Process prior to PBI first aid removal	<p>If a patient with suspected/confirmed funnel web spider bite presents to hospital without effective PBI first aid in place, immediately apply PBI first aid before proceeding further</p> <p>First aid measures for funnel web spider bite should remain undisturbed until all of the following steps have been undertaken (in most cases this will take 15 to 30+ minutes)</p> <ul style="list-style-type: none"> – The patient is admitted to hospital – An I.V. line is in place – The patient has been fully assessed including history and examination, noting symptoms present if any – at which point an assessment can be made about the need for antivenom – The doctor has assembled Funnel Web Spider Antivenom (preferably 4 vials) and the drugs that may need to be administered when the bandage and splints are removed – Adrenaline and resuscitation equipment are immediately available in case of a severe adverse reaction to antivenom. [Anaphylaxis, though unlikely due to the catecholamine storm in funnel web spider envenoming, remains a potential risk]
After completing the above steps	<p>If the patient has significant envenoming requiring antivenom therapy, antivenom should be commenced and symptoms should begin to subside prior to removal of first aid. After removal of PBI first aid, observe the patient carefully in case systemic envenoming recurs</p> <p>Alternatively, if the patient does not have signs of systemic envenoming at presentation and antivenom is readily available, remove PBI first aid and fully reassess 1 hour later (or sooner if symptoms/signs of envenoming develop more rapidly).</p> <p>A patient who remains symptom free at 4 hours post bite with first aid removed for at least 2 hours, may be discharged^{7,14}</p>

Spiderbite: Diagnosis

Principles of diagnosis and management^{3,8,9}

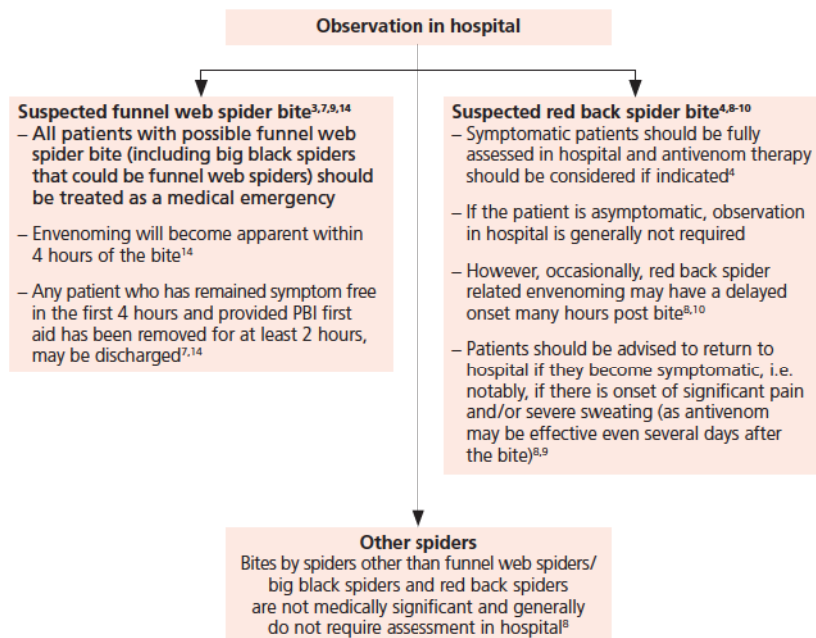
- Diagnosis of spiderbite is based on recognising the characteristic features of envenoming elicited through history and examination.
- In contrast to snakebite, laboratory tests are of no relevance for spiderbite.
- When managing spiderbite, the key question is whether there is evidence of significant envenoming, and if present, whether the pattern of envenoming reflects that of red back spider or funnel web spider, as each requires the appropriate antivenom.
- Key indications for each type of antivenom are provided in forthcoming sections covering funnel web spiders and red back spiders (pages 199 & 203).
- Non-specific local and general symptoms can arise as a consequence of any of the following.
 - Minor reactions to venom
 - Allergy
 - Infection
 - Anxiety
- Consequently, non-specific symptoms are **not** an indication for the use of antivenom.

186

When managing spiderbite, the key question is whether there is evidence of significant envenoming, and if present, whether the pattern reflects that of red back spider or funnel web spider

Spiderbite: Observation^{3,6}

For cases of suspected spiderbite, prolonged observation in hospital generally is not warranted.



187

Note: Any bite or sting can introduce secondary infection. Therefore, **all patients** should be advised of the symptoms of secondary infection and the need to seek medical attention, should these symptoms occur [8]. Research indicates that secondary infection following spiderbite is a rare occurrence [2].

Any patient [with suspected funnel web spider bite] who has remained symptom free in the first 4 hours and provided PBI first aid has been removed for at least 2 hours, may be discharged

Spiderbite: Diagnosis

History

Obtaining a thorough history is key to the diagnostic process in spiderbite (Table 28).

Table 28. Spiderbite cases: Taking a detailed history^{8,9}

Circumstances of the bite	<ul style="list-style-type: none"> – Time of day – Activity/what the patient was doing at the time of bite – Geographic location to limit the range of spiders to be considered – Was the spider actually seen biting the patient? – Number of bites – because multiple bites are potentially more severe
Details of the spider if seen	<ul style="list-style-type: none"> – Size – Colouration – Distinguishing features
Symptoms, including time of onset	<ul style="list-style-type: none"> – See Table 30 on page 190 for key symptoms/signs of envenoming based on spider species
Details of first aid	<ul style="list-style-type: none"> – Type of first aid – Any delay in application
Medical history and medications	<ul style="list-style-type: none"> – Past exposure to spiderbite or antivenom – Allergy history – Significant pre-existing medical conditions such as cardiac or renal disease – Medications

Examination

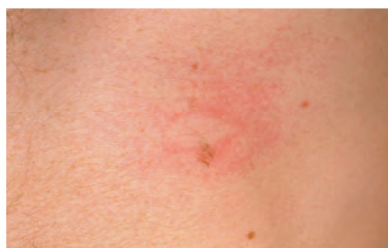Table 29. Spiderbite cases: Physical examination^{8,9}

ABC	Check airway, breathing and circulation and assess the presence of any immediate life threats
Bite site	Look for: swelling; sweating; piloerection; erythema; multiple bites Obvious fang marks (funnel web spider bites)
Draining lymph nodes	Tenderness or swelling
General signs of envenoming	HR (tachycardia or bradycardia) BP (hypotension or hypertension) SpO ₂ – falling Respiratory rate – increased? GCS (Glasgow Coma Scale) – impaired state of consciousness
Specific signs of systemic envenoming	Refer to Table 30 on key early signs on page 190

189

Laboratory investigations^{8,9}

- Typically, laboratory investigations are of no assistance in diagnosing spiderbite or assessing the degree of envenoming.
- Laboratory testing would play a role only in cases where the cause of the bite is unknown and snakebite also needs consideration.



Red back spider bite.
Photo copyright A/Prof Julian White.

Spiderbite: Diagnosis

Key symptoms/signs of envenoming based on spider species

Obtaining a thorough history is key to the diagnostic process in spiderbite (Table 28).

Table 30. Key symptoms/signs for diagnostic decision making in spiderbite^{4,5,8-10,14,17}

Key symptoms	Key signs	Species to consider*
Immediate significant local pain	Two distinct fang punctures separated by several millimeters	Funnel web spider group (if within geographic range)* A number of other spider species may cause immediate pain and/or distinct fang marks
Paraesthesiae in lips ± twitching/fasciculation of the tongue		Funnel web spider group (if within geographic range)*
Respiratory distress	Increased respiratory rate, cyanosis, pulmonary oedema	Funnel web spider group (if within geographic range)*
	Increased salivation/lacrimation	Funnel web spider group (if within geographic range)*
	Marked local sweating ± piloerection	Funnel web spider group (if within geographic range)* Red back spider
	Hypertension	Funnel web spider group (if within geographic range)* Red back spider
Progressive severe pain in the bite site moving to the rest of the bitten limb/region		Red back spider
Severe abdominal/chest pain	No evidence of acute abdomen or myocardial ischaemia	Red back spider
Miserable, inconsolable infant	No specific local signs but may have erythematous rash	Red back spider
Triad of progressive severe local to regional pain, marked sweating and hypertension, or a triad of local bite site pain, sweating and piloerection		Red back spider

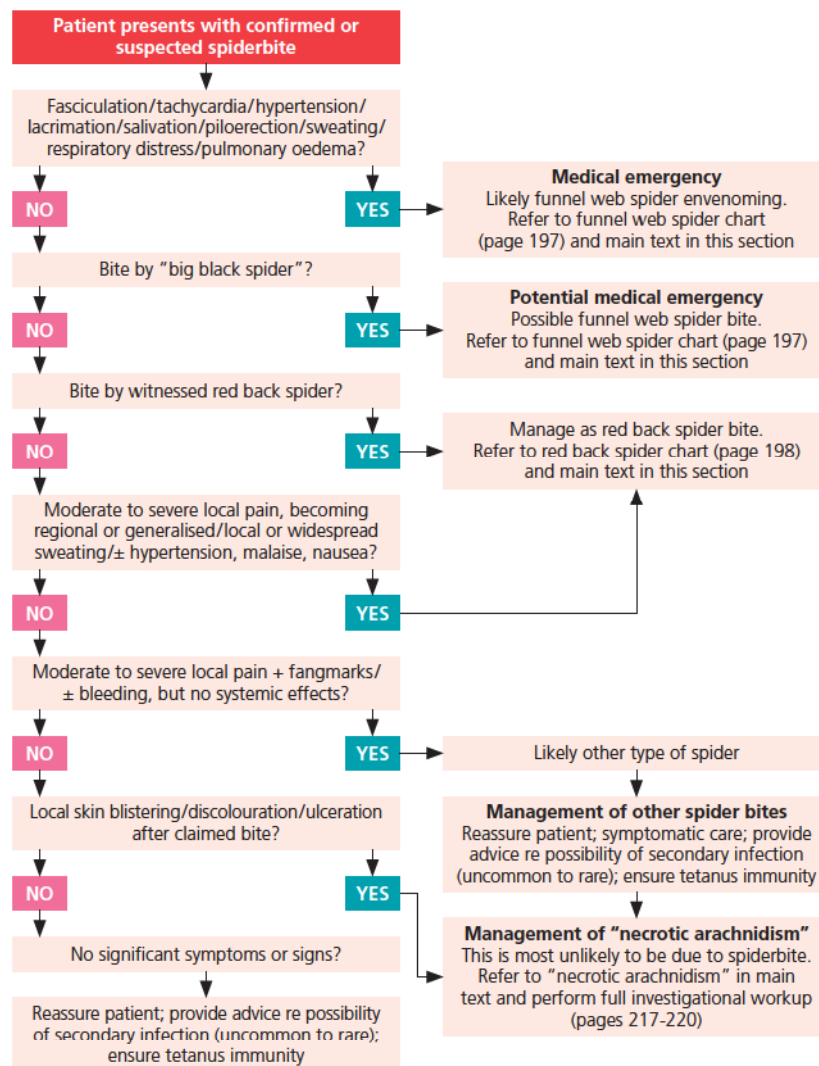
*With an increasing range of spiders being sold through pet shops, it is worthwhile bearing in mind that cases of spiderbite may at times present outside the range of distribution of the spider species.

Diagnostic algorithms⁸

- Diagnostic algorithms for bites from Australian spiders are designed to separate the two medically important groups (funnel web spider bite and red back spider bite) from all other cases, to ensure specific treatment, if indicated, can be offered at the earliest opportunity.
- Importantly, as always, the algorithms only cover common situations and cannot be expected to be accurate in every circumstance.
- Algorithms should be used only as a guide and in combination with good clinical judgment.
- A diagnostic algorithm for spiderbite based on the patient's clinical features is shown on page 192.
- In addition, Isbister and Sibbritt have developed diagnostic information based on geography and time of year.⁶
- While geography is clearly important given the limited range of distribution of the most medically significant spider species (funnel web spider) – it is important to bear in mind that with an increasing range of spiders being sold through pet shops, cases of spiderbite may at times present outside the range of distribution of the spider species.

Diagnostic algorithms for bites from Australian spiders are designed to separate the two medically important groups (funnel web spider bite and red back spider bite) from all other cases, to ensure specific treatment can be offered at the earliest opportunity if indicated

Spiderbite decision tree based on clinical presentation



Spider identification

Identifying a spider⁸

If the culprit spider is brought in with the patient, identifying the spider to at least a basic level can be valuable as it may help distinguish a potential funnel web spider bite (big black spider), *versus* some other type of spider not requiring further medical attention (the exception being the red back spider where diagnosis may be made on symptoms in the absence of a witnessed spider).

Spiders fall into two broad groups, which can be distinguished by external body characteristics (see page 194).

1. Mygalomorphs (funnel web spiders, trapdoor spiders, tarantulas, etc).^{7,9}
2. Araneomorphs (red back spiders, orb-weaving spiders, huntsman, wolf spiders, white tail spiders, black house spiders, etc).⁹

Consult with an expert when attempting to identify a spider – a photo may assist. Importantly, even with an expert's guidance, errors may occur during identification. Consequently the clinician should foremost be guided by the clinical picture. Do not rely on physical identification alone – ensure that the identity of the spider, if determined, correlates with the clinical features of the patient. If in doubt, rely on the clinical features.

Expert identification may be facilitated through the National Poisons Information Centre (Tel: 13 11 26), but will probably involve a clinical toxinology service and/or a State museum spider expert.

Finally, as always, clinical management of the patient should always take precedence over identification of the spider.

The clinician should foremost be guided by the clinical picture... ensure that the identity of the spider, if determined, correlates with the clinical features of the patient

Spider identification

Mygalomorph fangs



Araneomorph fangs

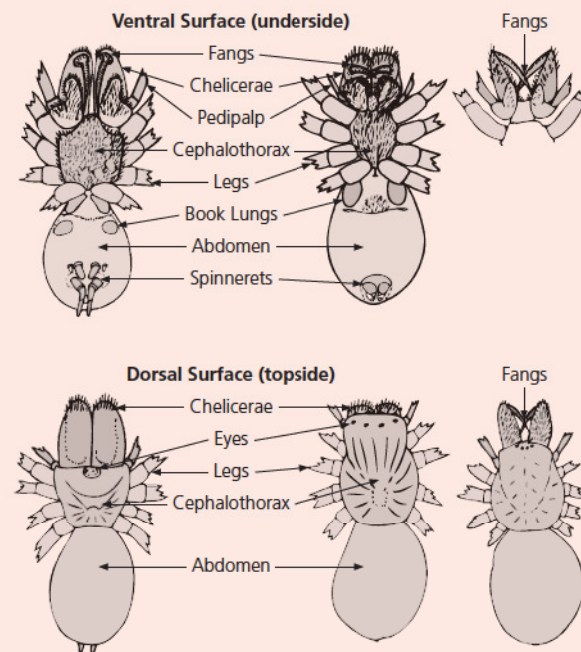


Identifying a spider

194

Mygalomorph spiders

Araneomorph spiders



Photos and diagram copyright A/Prof Julian White.

Management of envenoming due to spiderbite

Basic principles^{4,8,13,14}

- At the outset, it is crucial to identify cases that could potentially be severe (i.e. bites from the funnel web spider group) so that these patients are placed in a position where urgent specific treatment can be administered if indicated.
- Antivenom is the cornerstone of therapy for cases of systemic envenoming due to funnel web spider bite. Since the availability of antivenom, there have been no deaths from funnel web spider envenoming.
- Cases of suspected or confirmed red back spider bite also should be identified so that appropriate treatment can be offered if and when indicated. Antivenom therapy will be indicated for some cases.
- All other spiderbites require reassurance and appropriate advice to the patient regarding the potential (if rare) of problems such as secondary infection.
- Patients presenting with a putative diagnosis of “necrotic arachnidism” require complete work up for causes of skin damage, leaving “necrotic arachnidism” as an uncertain diagnosis of last resort only (see page 220).

195

At the outset, it is crucial to identify cases that could potentially be severe (i.e. bites from the funnel web spider group)

Management of envenoming due to spiderbite

Urgent treatment^{5,7,8,14}

In general, urgent treatment will only apply to definite and suspected funnel web spider bite.

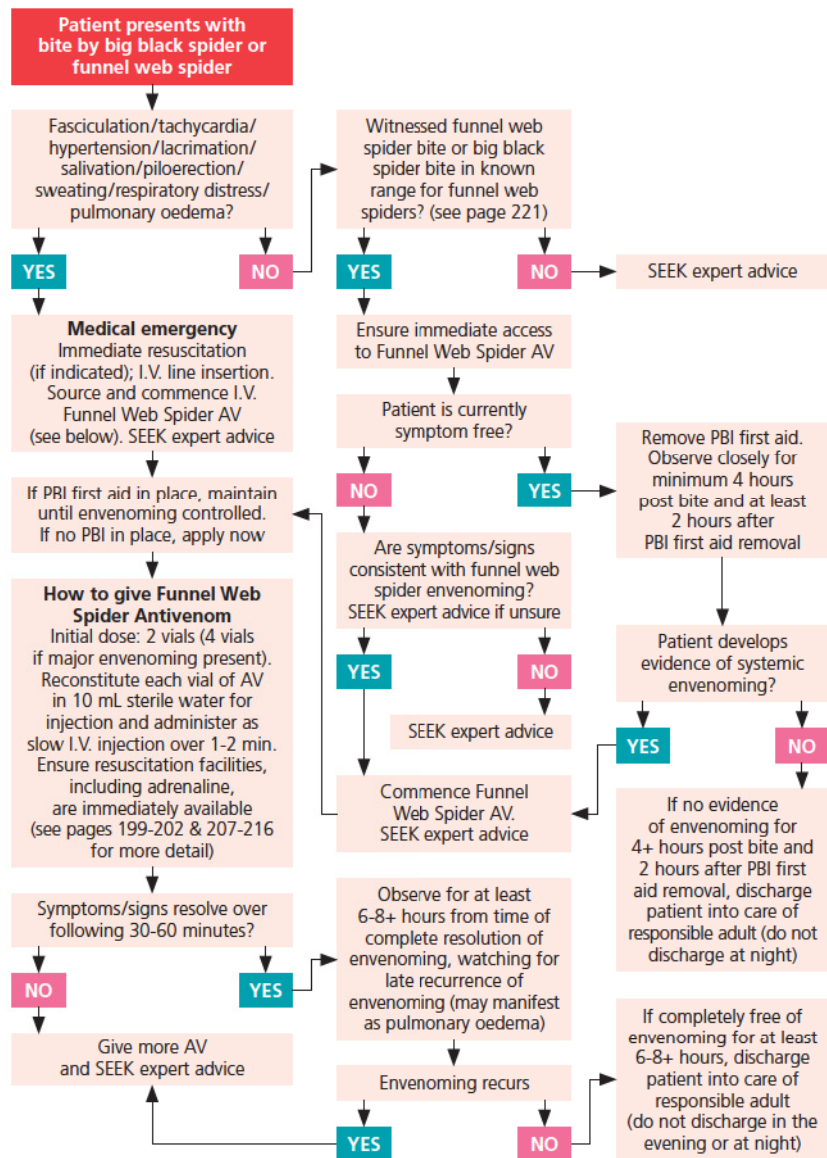
1. ABC: Ensure adequate respiratory and cardiac function.
Assess and maintain airway.
Provide respiratory support as indicated.
2. Assess if effective PBI first aid is in place. If not, apply PBI.
3. Insert I.V. line and provide fluid load.
Choice of crystalloid is not critical (e.g. normal saline, Hartmann's solution, etc).
4. Perform key history and examine patient as part of the diagnostic process (see pages 188-189).
5. Urgently assess history and examination findings to determine if systemic envenoming is present (see page 182 for symptoms and signs of envenoming).
If systemic envenoming has occurred, antivenom therapy with bioCSL's Funnel Web Spider Antivenom is indicated before removal of first aid.

If there is no evidence of significant envenoming and antivenom is readily available, remove first aid and re-evaluate over the next few hours to at least 4 hours from time of bite and at least 2 hours after removal of first aid.

Always seek expert advice when managing a patient who may have been bitten by a funnel web spider or requires antivenom therapy.

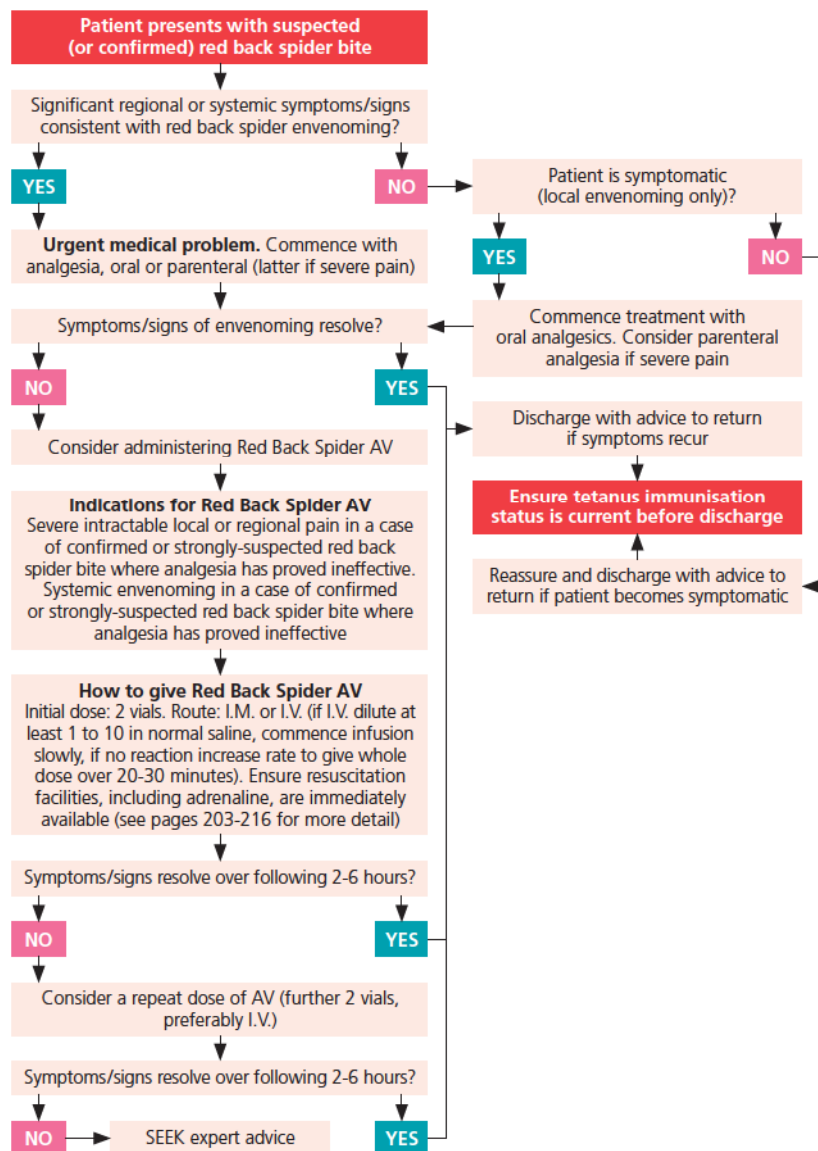
Urgently assess findings. If systemic envenoming is present, antivenom therapy with bioCSL's Funnel Web Spider Antivenom is indicated before removal of first aid

Management of suspected or confirmed funnel web spider bite



Management of suspected or confirmed red back spider bite

198



Specific treatment for funnel web spider bite: Antivenom

Indications for antivenom therapy

For funnel web spider bite, specific treatment involves administration of antivenom provided this is clinically indicated – i.e. if there is clear evidence of systemic envenoming (see box).²⁰ If systemic envenoming has occurred, seek expert advice.

Indications for funnel web spider antivenom therapy⁵

- Any degree of systemic envenoming consistent with funnel web spider bite, even just early symptoms (oral paraesthesia; tongue fasciculation) in a case of suspected or confirmed funnel web spider or big black spider bite – **except** where more than 4 hours have elapsed post bite, first aid has been removed for at least 2 hours, and the symptoms have not progressed beyond mild envenoming for at least 2 hours.^{7,14}
- Any patient who has been bitten by a spider that is possibly a funnel web spider, and who develops excessive salivation or lacrimation, or twitching of the tongue, piloerection, significant tachycardia, respiratory distress, hypertension if previously normotensive (patient may become hypotensive late in the syndrome), or disorientation, confusion or depressed level of consciousness, should be assumed to have systemic envenoming and should receive antivenom.

Timing of antivenom therapy

Funnel web spider envenoming can progress quickly from the first signs of envenoming to life-threatening envenoming, which could potentially occur in 30 minutes or less, especially in children.⁵

Clinical experience indicates that antivenom can reverse even advanced envenoming,¹⁴ so it is almost never too late to try antivenom, but clearly the sooner it is given once systemic envenoming develops, the greater the likelihood of a good outcome.⁸

Since the majority of bites by funnel web spiders do not result in significant envenoming and therefore do not require antivenom,^{7,9} there is no justification for routine antivenom administration in every case of funnel web spider bite. Antivenom should be reserved only for those cases that develop systemic envenoming.²⁰

Specific treatment for funnel web spider bite: Antivenom

Initial dose of bioCSL's Funnel Web Spider Antivenom

- Initial dose is 2 vials.²⁰
- Use 4 vials if envenoming is already severe.^{5,21-23}

The Product Information for bioCSL's Funnel Web Spider Antivenom does not specifically list this recommendation.²⁰

The advice regarding a higher initial dose of 4 vials for severe cases is based on published expert clinical experience and spiderbite management guidelines.^{5,21-23}
- Be prepared to give more antivenom if required, especially for severe cases.^{20,22,23}

The requirement for and timing of follow-up antivenom are determined on a case-by-case basis.²⁴

Typically, repeat dosing is performed within 15 minutes of the initial dose.^{20,24}

200

Follow-up dosing: bioCSL's Funnel Web Spider Antivenom

- Further antivenom may be required if there is continued or progressive systemic envenoming.^{5,20}
- If there has been an initial response, followed by later return of respiratory distress without other features of envenoming (such as salivation and lacrimation), it is quite possible this is due to further venom entering the circulation, and more antivenom may be needed.⁸
- Another possible explanation in this situation, at least in children, is that they are developing pulmonary oedema due to overload of I.V. fluids.^{8,22,23}

Unless overload of I.V. fluids is clearly the explanation, err on the side of further venom effect and administer more antivenom.⁸

If the respiratory impairment is mild, it might be reasonable to try a diuretic, such as frusemide as first-line therapy, but if this does not work, or respiratory distress worsens or is severe, use antivenom.⁸

Route of administration of bioCSL's Funnel Web Spider Antivenom

bioCSL's Funnel Web Spider Antivenom should be administered I.V. (as slow I.V. injection – see page 208).²⁰

Monitoring patients after antivenom therapy

- While clinical experience indicates that funnel web spider antivenom is efficacious, with a low risk of relapse provided an adequate dose of antivenom has been administered,²⁴ relapse has been known to occur more than 6 hours after antivenom therapy.^{22,23}
- Additionally, expert opinion suggests that the nature of funnel web spider envenoming including its rapidity of development and multi-system effects, necessitates prolonged observation prior to discharge. Therefore, patients with systemic envenoming should be admitted overnight post antivenom therapy.²⁴
- A systematic review of cases of funnel web spider bite presenting to hospitals in Australia indicates that for cases of severe envenoming who received antivenom therapy, the median stay in hospital was 1.8 days.¹⁴

201

Expert opinion suggests that the nature of funnel web spider envenoming necessitates prolonged observation prior to discharge patients should be admitted overnight post antivenom therapy

Important note

Prior to administering bioCSL's Funnel Web Spider Antivenom seek expert advice and please see additional information on pages 207-216 regarding preparatory procedures prior to antivenom therapy, administering antivenom, patient observation, and potential complications.

Specific treatment for funnel web spider bite: Antivenom

What if bioCSL's Funnel Web Spider Antivenom is not immediately available?

Antivenom is the key treatment for envenoming from funnel web spider bite. The availability of antivenom has dramatically altered outcomes and management *versus* the pre-antivenom era.¹⁴

In major funnel web spider envenoming, time is of the essence for administering antivenom therapy.^{3,5,8,17}

- If a patient bitten by a funnel web spider is asymptomatic, apply PBI first aid and transfer the patient to a hospital that stocks bioCSL's Funnel Web Spider Antivenom and has access to skilled clinicians.
- If a patient who is bitten exhibits symptoms of envenoming it may be preferable to move Funnel Web Spider Antivenom (and if possible, the skilled clinician) to the patient.

202

The following alternatives to antivenom treatment are based on past experience, prior to the availability of bioCSL's Funnel Web Spider Antivenom. Please bear in mind that during the pre-antivenom era, despite best efforts, survival was far from guaranteed. Seek expert assistance.⁸

- Severe intractable pulmonary oedema may be managed in ICU with intubation and mechanical ventilation (IPPV; PEEP), oxygen and possibly diuretics.
- Early hypertension and tachycardia, if severe enough, could be managed with sympathetic blockade (alpha blockade, not beta blockade).
- Later developing hypotension may respond to volume replacement and pressor agents such as isoprenaline. Atropine has been used with some success.
- There is limited evidence that PBI may allow local destruction of venom if left in place for a prolonged period.²⁵

In major funnel web spider envenoming, time is of the essence for administering antivenom therapy

Specific treatment for red back spider bite: Antivenom

Envenoming from red back spider bite

In Australia, red back spider bite is by far the most common cause of significant envenoming resulting in the administration of antivenom therapy.²⁶

Indications for bioCSL's Red Back Spider Antivenom

- Despite the frequency of red back spider envenoming and use of antivenom in Australia, recent controversial research has confounded the perception of the effectiveness of this antivenom,^{4,27,28} and therefore, the indications for the antivenom.
- Until the situation becomes clearer as the result of further research, the following indications (see box) should be considered broadly advisory only, and subject to clinical judgement on a case-by-case basis.⁸

Indications for bioCSL's Red Back Spider Antivenom

- Severe intractable local or regional pain in a case of confirmed or strongly suspected red back spider bite where analgesia has proved ineffective.^{4,8}
- Systemic envenoming in a confirmed or strongly suspected red back spider bite where analgesia has proved ineffective.^{8,29}

Timing of bioCSL's Red Back Spider Antivenom therapy⁸

- Clinical experience indicates that even parenteral analgesia with strong analgesics such as morphine may prove ineffective for the severe pain of red back spider envenoming.
- However, sufficient time should be allowed for analgesic therapy to show effectiveness before concluding it has failed and moving to antivenom therapy.

Specific treatment for red back spider bite: Antivenom

Dose of bioCSL's Red Back Spider Antivenom

Table 31. Dosing: bioCSL's Red Back Spider Antivenom

Initial dose	<p>2 vials^{22,23,30,31}</p> <p>One vial will neutralise 5 mg of venom <i>in vitro</i>. The actual amount needed in clinical practice may be more.²⁹</p> <p>Current treatment guidelines recommend 2 vials as a starting dose^{22,23,30,31}</p> <p>Please see additional information regarding dosing in the section immediately below this table</p>
Follow-up dosing	<p>Each follow-up dose is 2 vials^{22,23,30,31}</p> <p>Only severe cases are likely to require follow-up doses⁸</p> <p>A significant period (at least 2 hours) should be allowed between doses to evaluate effectiveness of the preceding dose^{22,23,29}</p> <p>Do not exceed a total of 4 vials (including the initial dose) without seeking expert advice^{22,23}</p> <p>Please see additional information in the section immediately below this table</p>

Note the doses in the above table differ from the Product Information for bioCSL's Red back Spider Antivenom.

- The Product Information for bioCSL's Red Back Spider Antivenom recommends:²⁹
An initial dose of 1 vial.
A follow-up dose of 1 vial (to be administered if envenoming has not reversed in 2 hours after the initial dose).
- The Product Information also states that further antivenom may be needed for some cases, but it is unusual to require more than 3 vials.²⁹
- The dosing advice in the above table is based on current (published) treatment guidelines, which recommend a greater number of vials for initial and follow-up dosing than that recommended in the Product Information.^{22,23,30,31}

Route of administration of bioCSL's Red Back Spider Antivenom

- Traditionally, bioCSL's Red back Spider Antivenom has been given I.M. However, in recent years, there has been a trend towards I.V. use.
- While there is a body of evidence substantiating the efficacy of the I.M. route,^{8,10} recent research contradicts this experience by indicating that I.M. antivenom is slow to achieve measurable circulating levels.²⁷
- Theoretically, I.V. is now the preferred route, as high blood levels will be achieved more rapidly and I.V. antivenom appears to have a low adverse reaction rate.^{26,27}
- Randomised controlled trials indicate comparable efficacy of I.M and I.V routes at 2 hours post antivenom but that more patients experience significantly improved pain at 24 hours post I.V. antivenom.^{28,32}
- Therefore, the expert panel involved in producing this handbook recommends administering bioCSL's Red Back Spider Antivenom I.V., preferably diluted in normal saline, Hartmann's solution* or similar, starting the infusion slowly and increasing the rate if no adverse reaction is observed.⁸
 - One method of I.V. administration involves using a 100 mL burette or similar, diluting the antivenom to 100 mL (a lower volume may be required in infants and small children), and administering via a pump.⁸
- However, given the body of past work, it remains acceptable to use the I.M. route (as recommended in the Product Information).^{8,29}

*The Product Information for bioCSL's Red Back Spider Antivenom recommends dilution using Hartmann's solution. The use of other isotonic crystalloid such as normal saline is based on expert clinical experience and is accepted current clinical practice [8,29,30].

Important note

Prior to administering bioCSL's Red back Spider Antivenom seek expert advice and please see additional information on pages 207-216 regarding preparatory procedures prior to antivenom therapy, administering antivenom, patient observation, and potential complications.

Specific treatment for red back spider bite: Antivenom

What if bioCSL's Red Back Spider Antivenom is not immediately available?

- While envenoming from red back spider bite can be unpleasant/distressing for the patient, it is not likely to be fatal.³
- The role of antivenom is to ameliorate symptoms and reduce the period of incapacity.
- In the absence of antivenom, there are no pharmacologic alternatives of proven efficacy. This explains the popularity of antivenom as a treatment.⁸

Some patients will respond to analgesia, most likely parenteral analgesia.

Pharmacologic agents such as diazepam have been used outside Australia for widow spider bite with mixed response.

Intravenous calcium infusions enjoyed limited popularity for widow spider bite in North America but their effectiveness has not survived clinical trials, and this treatment is not advised.

Patients should be reassured that symptoms will eventually resolve although sometimes it may take many days or longer to do so.

In the absence of antivenom, there are no pharmacologic alternatives of proven efficacy. This explains the popularity of antivenom as a treatment

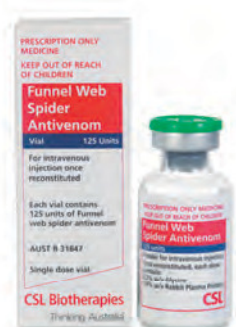Spider antivenoms: Preparation, administration and complications

Preparation prior to commencing antivenom therapy^{23,33,34}

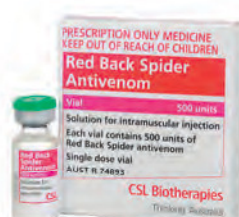Prior to commencing antivenom therapy, ensure all facilities are ready at hand to treat anaphylaxis, in the event that this should occur.

- Dedicate one small-bore I.V. line (18-20 G in adults) to antivenom administration.
- Dedicate one large bore I.V. line (16-14 G in adults) for emergency resuscitation.
- Prepare 1L normal saline (20 mL/kg in children) ready to administer under pressure.
- Prepare adrenaline (1:1000 – i.e. 1 mg adrenaline in 1 mL) drawn up to a dose of 0.01 mg/kg (maximum 0.5 mg – i.e. 0.5 mL) and label as 'Adrenaline for I.M. injection only (dose in mg)'.
- Ideally, also prepare an I.V. infusion of adrenaline 1 mg in 100 mL, which is controlled by infusion pump or syringe driver and ready to attach by a side arm to the resuscitation line. Anti-reflux valves must be attached above the side arm on any other infusions using this I.V. line, to prevent adrenaline going back up into other fluid bags. To prevent erroneous administration, **do not attach the adrenaline infusion unless it is needed.**
- Record blood pressure on the opposite arm to the fluid/adrenaline infusion – to avoid prolonged cuff inflations and thus, extravasation of infusion fluids.
- See 'What to do if there is an adverse reaction to antivenom' on pages 213-214 for method of emergency resuscitation if required.

207



bioCSL's Funnel Web Spider Antivenom.



bioCSL's Red Back Spider Antivenom.

Spider antivenoms: Preparation, administration and complications

How to administer spider antivenoms

Table 32. Administering bioCSL's Funnel Web Spider Antivenom^{5,8,20,24,30}

Treatment location	If possible, patients should receive Funnel Web Spider Antivenom in a monitored environment with immediate access to resuscitative equipment and one-to-one nursing
What to do about first aid	<p>If adequate PBI first aid was applied, the splint and pressure bandage should not be removed until after antivenom has been administered, as removal can precipitate significant effects of systemic envenoming</p> <p>See pages 184-185 on the timing of removal of PBI first aid for funnel web spider bite</p>
Route of administration	<p>Intravenous</p> <p>Always administer Funnel Web Spider Antivenom as a slow I.V. injection</p>
Dilution of antivenom	bioCSL's Funnel Web Spider Antivenom is formulated as a freeze-dried preparation. Reconstitute each vial to up to 10 mL with sterile water for injection
Time period of I.V. dosing	Administer each vial of reconstituted antivenom by slow I.V. injection (over about 1 to 2 minutes)

Table 33. Administering bioCSL's Red Back Spider Antivenom^{8,17,19,29,30,35}

Treatment location	If possible, patients should receive Red Back Spider Antivenom in a monitored environment with immediate access to resuscitative equipment and one-to-one nursing
What to do about first aid	First aid is not required for red back spider bite other than perhaps intermittent application of ice or a cold compress Note: PBI first aid is contraindicated for red back spider bite as it may worsen pain ¹⁹
Route of administration	Intravenous through drip set Alternatively, the intramuscular route also is an option (as per the Product Information)
Dilution of antivenom	For I.V. administration: – Dilute Red Back Spider Antivenom up to 1 in 10 or more with an isotonic crystalloid solution (e.g. normal saline; Hartmann's solution)* – dilution to 100 mL is often used in adults – To avoid fluid overload, use smaller volumes in small children and in adults with compromised cardiac function Adults with compromised cardiac function: Up to a 1 in 5 dilution may be more appropriate Small children: Dilute antivenom to the extent that the total volume delivered does not exceed 10 mL/kg For I.M. administration inject each vial undiluted
Time period of I.V. dosing	For I.V. administration, each dose of antivenom should be run over about 30 minutes (a single dose may comprise multiple vials). Start very slowly and increase the rate gradually to deliver antivenom over approximately 30 minutes

*The Product Information for Red Back Spider Antivenom recommends dilution using Hartmann's solution. The use of other isotonic crystalloid such as normal saline is based on expert clinical experience and is accepted current clinical practice [8,29,30].

Spider antivenoms: Preparation, administration and complications

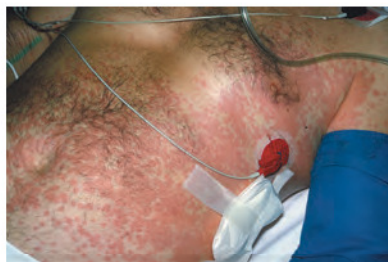Observation during antivenom therapy^{8,33,36}

- Carefully observe the patient during antivenom administration and for 1 hour after, to ensure adverse reactions (if they occur) are recognised and treated promptly (adverse reactions are discussed further on pages 213-216).
- In particular, look for the development of symptoms and signs of anaphylaxis. An erythematous rash may be the first sign of developing adverse reactions (often first seen in the axilla or the lower abdomen).
- Also observe for hypotension and bronchospasm.
- Carefully monitor BP, HR and respiratory function, oxygen saturation, with particular attention to development of hypotension and/or bronchospasm.
- Look for additional warning signs of anaphylaxis in children (Table 34).
- See pages 215-216 for further information on potential complications of antivenom therapy.

210

Table 34. Warning signs of anaphylaxis in children^{8,36}

Rash; hypotension; or bronchospasm	Profuse sweating
Nasal, palatal, or ocular pruritus	Faecal or urinary urgency or incontinence
Coughing	Abdominal pain
Sneezing	A sense of impending doom



Antivenom rash in an adult.

Photo copyright A/Prof Julian White.

Premedication prior to administering antivenom

Premedication prior to administering antivenom remains an issue surrounded by controversy, some conflicting evidence and opinion, and uncertainty about “best practice”.

Studies outside Australia have provided evidence showing premedication using antihistamines and/or hydrocortisone are either ineffective, or possibly effective to a variable extent.^{37,38} Hence, available evidence is unhelpful and contradictory for these medications. Similar contradictory evidence applies to adrenaline premedication within and outside Australia.³⁹⁻⁴³

Data from recent Australian clinical research reported in 2008 (the ASP study – a multicentre, prospective study of snakebite envenoming from over 60 major tertiary centres and regional hospitals around Australia) suggests that there is no clear benefit in giving premedication prior to antivenom administration, including no clear benefit in using adrenaline as premedication.⁴⁴

Further, the ASP study has shown that in Australia, the use of premedication prior to antivenom therapy is not common practice (adrenaline premedication was provided to 8.7% of patients in whom data about premedication was available).⁴⁴

Additionally, recent expert consensus suggests that premedication to prevent adverse reactions to antivenom therapy is not routinely indicated.³⁰

.... continued overleaf

Spider antivenoms: Preparation, administration and complications

Premedication prior to administering antivenom ... cont'd

Clearly, there may be specific clinical circumstances, judged on an individual patient basis, where a clinician may consider the use of adrenaline as premedication prior to antivenom administration. For example – in a patient with known major allergy to antivenom where resuscitation facilities may be suboptimal.⁸

In such situations the uncertain and unproven benefits of adrenaline premedication should be carefully weighed against the known and documented adverse effects from use of adrenaline, and wherever practical, the patient should be told of this risk-benefit situation so that informed consent can be given.⁸

Clearly, in some situations, with severe life-threatening systemic envenoming, informed consent is impractical and should not form a necessary condition of using adrenaline premedication if the clinician deems this is required.⁸

Irrespective of whether premedication is used or not, antivenom should only be administered in an environment where rapid detection and appropriate treatment of severe early adverse reactions will occur.⁸

- This includes the immediate availability of adrenaline, oxygen and resuscitation equipment and staff competent and prepared to use these treatments effectively.
- In such a setting, a controlled I.V. adrenaline dilute infusion may be the optimal route for administering adrenaline to treat anaphylactic or anaphylactoid reactions (see pages 213-214 for further details).⁸

Adrenaline premedication is considered redundant when treating significant envenoming from funnel web spider bite, due to the release of catecholamines during the process of envenoming.^{8,45}

What to do if there is an adverse reaction to antivenom^{23,33,36,44}

Adverse reactions may be related to the rate of antivenom infusion – those reactions can include flushing, hypotension or bronchospasm. Hypotension and bronchospasm are hallmarks of major adverse reaction (anaphylaxis).

Adverse reactions may respond to temporarily stopping the antivenom infusion, waiting to ensure that there is no return or worsening of the reaction, and then re-starting at a slower rate.

For anaphylactic reactions, adrenaline is generally the drug of first choice.

See the box below and on page 214.

Steps to take if there is either a sudden fall in blood pressure, or bronchospasm after starting antivenom infusion^{8,23,30,33,34,36}

- Suspend the antivenom infusion.
- Lie the patient flat (if not already in this position) and commence high-flow 100% oxygen and support airway/ventilation as required.
- Begin rapid infusion of one litre normal saline (20 mL/kg in children) over 2-3 minutes.
- Administer adrenaline 1:1000 I.M. into the lateral thigh at a dose of 0.01 mg/kg to a maximum of 0.5 mg (i.e. a maximum of 0.5 mL). Note: Adrenaline 1:1000 ampoule is 1 mg adrenaline in 1mL.
- Alternatively, those experienced with I.V. administration of adrenaline can proceed to do this directly instead of I.M injection. See procedure on page 214 in the section 'If adverse reactions do not respond to initial management'.
- Seek expert advice regarding ongoing management.
- In most cases, once the adverse reaction is controlled, cautious reintroduction of antivenom is possible. [Note: A patient requiring antivenom therapy prior to the adverse reaction will likely continue to require antivenom after the adverse reaction].

Note: The recommendations above and on page 214 for the management of anaphylactic reactions to antivenom reflect current published anaphylaxis management guidelines and expert advice and may vary from the Product Information for bioCSL's antivenoms [8,33,34,36].

.... continued overleaf

Spider antivenoms: Preparation, administration and complications

What to do if there is an adverse reaction to antivenom ... cont'd

If adverse reactions do not respond to initial management^{8,23,30,33,34,36}

- If hypotensive, repeat normal saline bolus as per box on page 213 (up to 50 mL/kg may be required).
- Commence I.V. infusion of adrenaline (0.5-1 mL/kg/hr of adrenaline 1 mg in 100 mL) and titrate according to response. Monitor BP every 3-5 minutes using the arm opposite to the infusion.
- Be aware that as the adverse reaction to antivenom resolves, adrenaline requirements will fall, the blood pressure will rise and the adrenaline infusion rate will need to be reduced.
- Consider nebulised salbutamol for bronchospasm, nebulised adrenaline for upper airway obstruction, and I.V. atropine for severe bradycardia.
- Seek advice urgently from local/regional ED Consultant and/or ICU Consultant.
- In most cases, once the adverse reaction is controlled, cautious reintroduction of antivenom is possible. [Note: A patient requiring antivenom therapy prior to the adverse reaction will likely continue to require antivenom after the adverse reaction].

214

Antivenom therapy: Commonest mistakes⁸

Some of the most common mistakes relating to antivenom therapy are highlighted below.

- Failure to use antivenom when clearly indicated.
- Giving antivenom unnecessarily, i.e. when there are no clear clinical indicators of significant systemic envenoming.
- Choosing the wrong antivenom.
- Choosing the wrong dose.
- Antivenom given too late. [However, for envenoming from red back spider bite, delayed antivenom therapy (by a day or more) may still be effective].⁹
- Administering antivenom by the wrong route.
- Failing to prepare for an adverse reaction.
- Failing to inform the patient about serum sickness.

Complications of antivenom therapy

Essentially, antivenom is whole or modified antibody from an animal. It is obtained by hyperimmunising the animal against a particular venom or group of venoms. The IgG antibody from blood plasma is used, and typically, is fractionated to the F(ab')₂ fragment of IgG, and on occasion, whole IgG. bioCSL's Funnel Web Spider Antivenom is a purified whole IgG preparation fractionated from rabbit plasma. bioCSL's Red Back Spider Antivenom is derived from horse plasma, with the IgG antibody fractionated to the F(ab')₂ fragment.^{20,29,46}

When making antivenoms, bioCSL undertakes assiduous efforts to filter and discard any extraneous blood components and contaminants. Nevertheless even high-quality antivenoms will cause adverse reactions in some patients. The clinically important adverse reactions can be subdivided into 'early' and 'late'.

Early and late adverse reactions to antivenom

Early reactions are those that occur immediately after commencing antivenom therapy or within the first few hours (Table 35). Late adverse reactions may occur several days later (Table 36 on page 216).

Table 35. Early adverse reactions to antivenom^{8,20,29,30,33,36}

Rash	Localised or generalised erythematous, sometimes pruritic rash. May occur as an isolated and generally trivial adverse reaction or it may herald the onset of a more severe adverse reaction
Pyrexia	Febrile reactions may potentially occur
Anaphylactic/anaphylactoid reaction	<p>This is a type of potentially life-threatening reaction. Therefore, antivenom should never be given until measures to manage such a reaction are in place. This is why the use of antivenom outside a hospital environment is strongly discouraged. Note however, when antivenom is clinically indicated, it should never be withheld for fear of an adverse reaction. Seek expert advice</p> <p>Anaphylaxis may be preceded by a localised or generalised rash, sometimes first seen in the axilla or lower abdomen, proceeding to hypotension and/or bronchospasm</p> <p>Look for additional warning signs of anaphylaxis in children (see Table 34 on page 210)</p>

Spider antivenoms: Preparation, administration and complications

Table 36. Late adverse reactions to antivenom^{8,20,29,30}

The principal late adverse reaction to antivenom is serum sickness, a type III delayed hypersensitivity reaction, which most commonly presents 4–14 days post exposure

Serum sickness is characterised by a flu-like illness with fever, joint and muscle pain and general malaise, often preceded by or associated with a maculopapular or erythema multiformae-like rash

Serum sickness rates often increase as the antigen load increases. Therefore, it is more likely to occur in patients who have had a high volume load of antivenom

Every patient who receives antivenom should be advised of the symptoms of serum sickness and told to seek medical care if these symptoms arise after discharge from hospital

216

Serum sickness is more likely to occur in patients who have had a high volume load of antivenom

Management of serum sickness^{8,30,47}

- While serum sickness can be a mild and self-limited disease, it can be distressing for patients and early diagnosis and treatment is advisable.
- There is a diversity of opinion about the approach to treatment for various causes of serum sickness (i.e. not just antivenom) – which may involve first-line use of antihistamines or oral steroids. Serum sickness post antivenom therapy is usually managed with a short course of oral corticosteroids.
- If uncertain about the treatment approach, consult with a clinical immunologist.
- Some experts suggest prescribing a week-long course of oral prednisolone commencing immediately after antivenom, for all patients who have received more than 25 mL of antivenom. This treatment has not yet been tested through clinical trials.

Necrotic arachnidism

Necrotic arachnidism: Evidence *versus* mythology

The problem of necrotic lesions or ulcers and their purported association with bites by the white tail spider is clouded by much speculation and mythology. Although necrotic lesions attributed to white tail spider bites have been reported in the literature, the reports lack evidence of an identified white tail spider biting the patient.¹²

In contrast, in recent years, prospective studies of confirmed spiderbite provide strong evidence that in Australia, spiderbite in general and the white tail spider specifically, do not cause skin injury/necrosis.^{2,12}

- In one study of 750 cases of definite spiderbite, not a single case of necrotic ulcers was seen.²
- In another study of 130 patients with confirmed white tail spider bite, three characteristic patterns of clinical effects were associated with the bites (pain only; pain and red mark for less than 24 hours; a persistent painful or irritating red lesion). However, no necrotic ulcers developed as a consequence of white tail spider bite.¹²

Furthermore, in a study of eleven patients with skin lesions or necrotic ulcers referred to the Hunter Area Toxicology Service, a diagnosis other than spiderbite was made in all 9 cases where appropriate investigations and follow up was possible (see box on page 218). Only one patient recalled witnessing a spider biting (although all cases had been initially referred as white tail spider bites or necrotic arachnidism).¹³

.... continued overleaf

In a study of 130 patients with confirmed white tail spider bite... no necrotic ulcers developed as a consequence of white tail spider bite

Necrotic arachnidism

Necrotic arachnidism: Evidence *versus* mythology ... cont'd

Non-spiderbite causes of necrotic skin lesions or ulcers¹³

In 9 patients with skin lesions/ulcers thought to be 'white tail spider bite or necrotic arachnidism' appropriate investigations and follow up led to the following diagnoses:

- Dermatophytoses [2 cases]
- Staphylococcal infections [3 cases]
- Pyoderma gangrenosum [1 case]
- Cutaneous polyarteritis nodosa [1 case]
- *Nocardia braziliensis* [1 case]
- Infected diabetic ulcer [1 case]

218

It is apparent that in Australia, necrotic ulcers are unlikely to be caused by white tail or other spiders. Hence, all patients presenting with ulcers or necrotic lesions should be properly investigated (bacterial, fungal and mycobacterial cultures and skin biopsy for histopathology) – see chart on page 220.^{2,12,13}

Other types of spiders, particularly those outside Australia, can cause primary skin necrosis. Foremost among these is the recluse spider group (loxoscelism), including the fiddlbeback spider, *Loxosceles rufescens*. *Loxosceles rufescens* is now clearly implicated in two South Australian cases of necrotic arachnidism.²³ However, these appear to be isolated cases, with no subsequent cases noted in recent years. Therefore, it is unreasonable to invoke loxoscelism as a likely cause of necrotic skin lesions following suspected bites in Australia.⁸

All patients presenting with ulcers or necrotic lesions should be properly investigated (bacterial, fungal and mycobacterial cultures and skin biopsy for histopathology)

Consider necrotic arachnidism only if there is initial pain, then blistering and dusky colouration of the skin, developing over 2-7 days, with later darkening of the skin, preferably with a witnessed spiderbite – **but only after all other causes have been excluded**.²³ At this time, necrotic arachnidism is an unsubstantiated diagnosis in the Australian clinical setting.^{2,12,13}

Although necrotic arachnidism has been a problem in the US for some time, treatment approaches remain controversial. Early surgical intervention, steroids or antibiotics appear to confer little benefit. Nevertheless, if secondary infection develops, this will clearly require treatment. There is anecdotal evidence supporting the use of hyperbaric oxygen therapy. However, firm evidence is lacking and use is limited by the impracticality of treating every case in this manner. In Brazil, where loxoscelism is considered 'common', antivenom is routinely used, but the evidence for effectiveness is unclear.^{8,9,23}

At this time, necrotic arachnidism is an unsubstantiated diagnosis in the Australian clinical setting

Necrotic skin lesions: Approach to investigations

220

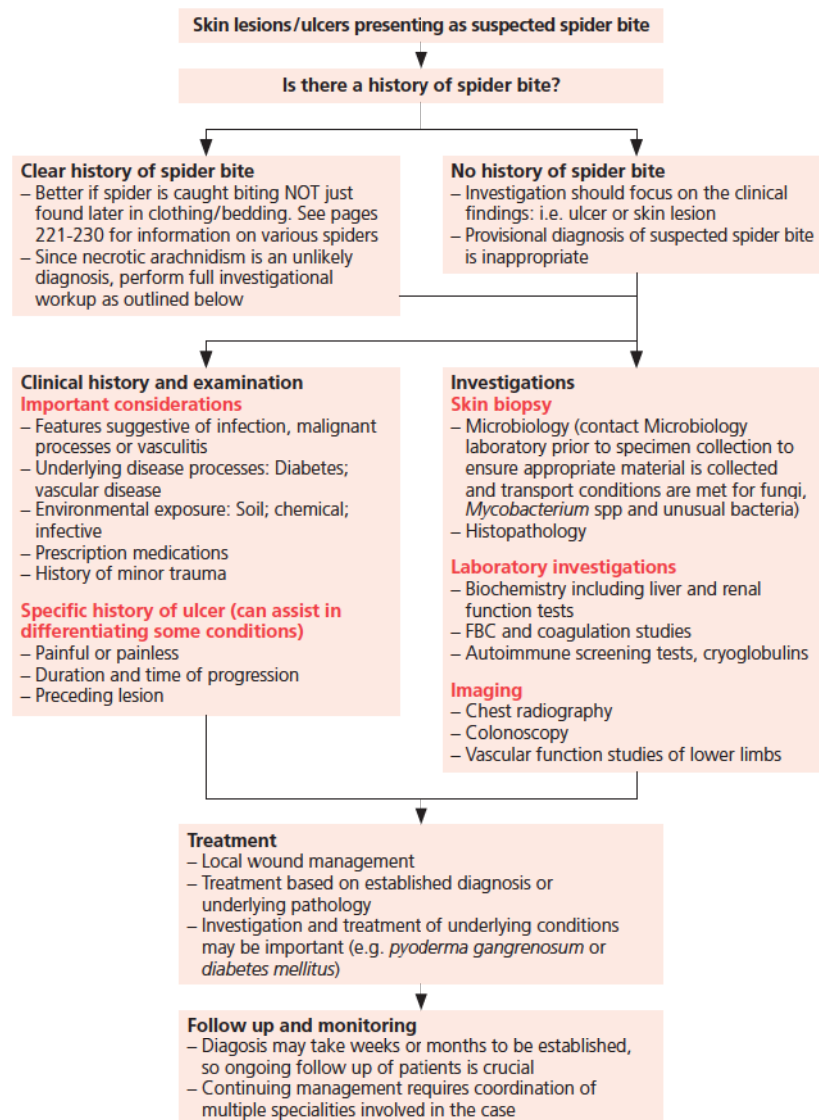


Figure copyright A/Prof Julian White. Investigational work-up information obtained by A/Prof White from Isbister and Whyte *Intern Med J* 2004; 34: 38–44.

Australian spiders overview: Funnel web spider group

The species^{7,9}

- There are at least 35 species of funnel web spiders in 2 genera, *Atrax* and *Hadronyche*.
- All are medium to large, robust spiders, mostly dark or black in colour, with stout legs and large fangs. Both males and females build silk tube retreats, usually in the ground.
- Males leave these retreats in search of female mates, a process which may increase the chance of adverse interaction with people, as the wandering males may get underfoot, into shoes, boots or clothing left on or near the floor.

Distribution^{5,7,9,14,15}

- Funnel web spiders have a wide distribution throughout south east Australia, including Tasmania (see map).
- However, thus far, the species proven to be dangerous to humans have a more limited range, largely limited to eastern parts of NSW and SE Queensland.
- The only proven killer, the Sydney funnel web spider *Atrax robustus*, is restricted to the Sydney region and adjacent areas, approximately 160 km radius north, south and west of the city, including Gosford and Newcastle. However, clinical experience and venom studies indicate at least several other species are potentially lethal and these cover, collectively, a far wider range than the Sydney species alone. [A case of funnel web spider envenoming in inner-city Brisbane has been described recently, which has wider implications regarding stocking of antivenom].¹⁵

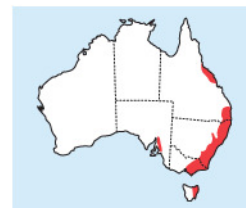221



Female Sydney funnel web spider *Atrax robustus*.



Female tree funnel web spider, *Hadronyche formidabili*.



Australian funnel web spiders: distribution.

Australian spiders overview: Funnel web spider group

Venom composition^{9,48}

- Funnel web spider venom is multicomponent, but a protein toxin, δ -hexatoxin-Ar1a (previously named robustoxin or atracatoxin), is the principal component responsible for severe envenoming in humans.
- Interestingly, while many mammals are relatively unaffected by funnel web spider venom, humans are very sensitive to it.
- δ -hexatoxin-Ar1a causes stimulation of the nervous system at a variety of synapses, with rapid and devastating effect.

Clinical effects

- Despite its fearsome reputation, there are only 13 recorded deaths due to funnel web spider bite,^{14,49} and experience indicates that many bites do not result in significant envenoming.^{2,7}
- However, when the spider does inject a dangerous quantity of venom, the effects can be rapid and severe, and death may occur within an hour.^{5,14}
- Consequently, all cases of suspected funnel web spider bite must be treated as a potential medical emergency.^{3,9}
- Typically the bite site is painful (due to large fangs), and the spider is usually seen.^{7,9}
- If envenoming occurs, it will develop early, starting with tingling around the lips, twitching of the tongue, then profuse salivation, lacrimation, sweating, piloerection and muscle twitching/spasms.^{5,9,14}
- Hypertension and tachycardia are features, as is respiratory distress due to rapid development of pulmonary oedema, which may be very severe and potentially lethal. In the early stages this may be mistaken for organo-phosphate poisoning. Convulsions may occur.^{5,8,9,14}

Australian spiders overview: Red back spiders

The species^{3,4}


- Red back spiders usually build webs under objects, with drop lines to the ground or other flat surface. Thus, they are commonly found under lower shelves, the bottom rails of fence lines, in refuse areas, especially old car bodies, even on the underside of seats left outside and in the recesses of cupboards indoors!
- Only the female is dangerous to humans, although on rare occasions, the male may bite and cause at least local envenoming.
- As the spiders tend not to wander, most bites occur when the person comes in contact with the web structure.
- Cupboard spiders *Steatoda* sp are close relatives of the red back spider and are commonly found in and around human habitation. They are mentioned here because they can also bite and cause symptoms similar to red back spiders, but generally less severe. Physically they look very similar to red back spiders, but lack red markings on the abdomen.

Distribution¹⁸


Red back spiders are found throughout Australia, in essentially all habitats, from very arid through to tropical, and they are common in urban areas, where most bites occur.

Venom composition¹⁸

The venom is multicomponent, with a family of protein toxins, the latrotoxins, most prominent. One of these, α -latrotoxin, stimulates neural synapses throughout the body with wide-ranging effects.



Red back spider (female),
Latrodectus hasselti.



Cupboard spider, *Steatoda grossa*
(looks similar to red back spider
but without red markings)

Photos copyright A/Prof Julian White.

Australian spiders overview: Red back spiders

Clinical effects

- The clinical features of major envenoming by red back spiders are sometimes wide ranging in extent and may mimic other conditions, but rarely are lethal.^{3,9,10}
- Antivenom therapy should be considered for cases of significant envenoming.⁴
- The classic effective red back spider bite is felt as a mild sting only, with little to see at the bite site.¹⁰
- Between 10-40 minutes later (sometimes longer), the bite site becomes painful.^{10,18}
- The pain becomes severe over a variable timeframe, extending proximally and involving draining lymph nodes in the axilla or groin.^{9,10,18}
- There is often local sweating.^{9,10,18}
- The pain may then spread to the abdomen, chest, neck or head, often associated with profuse sweating, either localised or general, mild to severe hypertension, and malaise with nausea.^{9,10,18}
- Classic presentations include:
 - A triad of progressive severe pain, marked sweating and hypertension.^{4,8,9}
 - A triad of local bite site pain, sweating and piloerection.¹⁷
 - Gravitation of symptoms to the lower limbs in delayed presentations – i.e. burning sensation in the soles of the feet and pain and profuse sweating of both lower legs even if the bite was elsewhere.^{8,10}
- Many other symptoms or signs may occur, but the above are clinically most consistent and useful for diagnosis.⁸
- The progression from local to generalised pain may occur within 1 to 3 hours, or take up to 24 hours.⁸⁻¹⁰

.... continued


Antivenom therapy should be considered for cases of significant envenoming

- In infants, general miserableness, refusal of feeds, inconsolable crying, and sometimes a non-specific erythematous rash are key features of red back spider bite.⁹
- Occasionally the initial bite may not have been noticed and the patient may present with abdominal or chest pain. In such cases, careful questioning will usually elicit a history of possible exposure to spiderbite and initial localised pain, pointing to the true diagnosis.^{4,8,9}
- In pregnancy, the generalised abdominal pain of red back spider bite may appear similar to the onset of premature labour. Usually a clear history of a bite with initial local pain will be available.⁸
- Bites by cupboard spiders (*Steatoda sp*) can cause similar symptomatology, although generally not severe.³

In infants, general miserableness, refusal of feeds, inconsolable crying, and sometimes a non-specific erythematous rash are key features of red back spider bite

bioCSL's Red Back Spider Antivenom

- bioCSL's Red Back Spider Antivenom has been developed purely for use against bites by the Australian red back spider.²⁹
- However, there is some evidence of the efficacy of this antivenom in neutralising the *in vitro* effects of venom from other black widow spiders, and in the management of significant envenoming by cupboard spiders (*Steatoda spp*).^{50,51}



Red back spider (female),
Latrodectus hasselti.

Photo copyright A/Prof Julian White.

Australian spiders overview: Mouse spiders

- Mouse spiders (*Missulena spp*) are ground-dwelling mygalomorph spiders with large fangs and venom which is similar to that of the funnel web spider.
- A single severe (but non-fatal) paediatric case from SE Queensland has been reported (with symptoms/signs similar to those of envenoming by funnel web spider).¹⁶
- A study of 40 confirmed cases (including the one in Queensland) found that:¹⁶
 - Only the QLD case developed significant envenoming (with hypertension, muscle spasms, opisthoclonus and unconsciousness), which appeared to respond to bioCSL's Funnel Web Spider Antivenom.
 - Of the remaining 39 cases, 6 showed local neurotoxic effects (paraesthesiae, numbness and diaphoresis) and 5 had minor systemic effects (headache, nausea).

226

- Therefore, mouse spiders, while technically capable of causing major envenoming, in practice are unlikely to do so.¹⁶
- In practical terms, based on the similarity of envenoming signs/symptoms between these big black spiders and funnel web spiders, cases of mouse spider bite in eastern Australia (i.e. within the range of distribution of funnel web spiders) should be observed in an emergency department for 4 hours after the bite (and at least 2 hours after PBI first aid removal) to exclude major envenoming (see page 197).^{7,16}
- In areas outside the range of distribution of funnel web spiders, a shorter (1-2 hours) observation period would be appropriate.¹⁶
- Should severe envenoming occur, consider the use of bioCSL's Funnel Web Spider Antivenom, although this is not yet an approved indication.^{8,16}



Male mouse spider,
Missulena spp.

Photo copyright A/Prof Julian White.

Australian spiders overview: Other spiders

White tail spider *Lampona cylindrata*

- This common hunting spider, found in houses, has been erroneously linked with necrotic arachnidism.
- A large published case series of 130 definite bites by white tail spider with expert identification of the spiders, described a pattern of clinical effects including local short-lived pain and erythema, sometimes with mild swelling or lump formation that can persist for a few days, but no instances of either secondary infection or ulceration/necrosis.¹²
- Research on white tail spider venom also has failed to confirm the association with skin damage.¹²
- Thus, the white tail spider can now be excluded as a cause of necrotic arachnidism.^{2,12,13}
- Suspected bites by unknown organisms, causing ulceration should NOT be labelled as “white tail” spider bites.¹³
- Other, non-bite causes of skin ulceration/necrosis should be considered in these cases with possible spiderbite left as a diagnosis of last resort, once all else is excluded (see pages 217-220).¹³



White tail spider,
Lampona cylindrata.

Australian spiders overview: Other spiders

The black house spider *Badumna insignis*⁵²

- This is a robust black spider of family Desidae, found in untidy webs with a tube retreat.
- It is common in urban habitats.
- The bite can cause moderate, and sometimes severe local pain of short duration, with erythema and swelling, and occasionally mild systemic symptoms.
- A recent series of 25 prospectively identified definite cases confirms that the black house spider is not a likely cause of “necrotic arachnidism”.

Huntsman spiders¹¹

- There are many species of huntsman spiders, family Sparassidae, which are common inside houses.
- Bites are generally very mild, with short-lived pain (approximately 5 min), reportedly severe in 27% of cases.
- Bite marks and local bleeding are more common than for bites by other spiders.
- In a minority of cases, local mild swelling, itchiness and erythema can all occur.
- A few species can occasionally also cause mild systemic symptoms, notably headache and nausea.
- A large series of 168 definite cases of huntsman spider bite has confirmed that these spiders **do not** cause skin damage/ulceration/necrosis.

228



Black house spider,
Badumna insignis.



Huntsman spider,
Isopeda spp.

Wolf spiders⁵³

- Many species of these ground hunting spiders, family Lycosidae, are common in gardens, sometimes entering houses.
- A reported series of 45 confirmed cases described bites by these spiders as generally minor, causing short-lived local pain, sometimes severe, local erythema, with occasional swelling and itchiness.
- Puncture marks/bleeding occurs in about a third of cases.
- Very few cases develop systemic symptoms, all temporary and minor (nausea, headache, malaise).
- There are no cases of skin damage/ulceration/necrosis associated with bites by wolf spiders.

Tarantula spiders⁸

The common name 'tarantula' covers many spiders across a number of genera. These often large, hairy mygalomorph spiders of the family Theraphosidae, are increasingly common as indoor "pets".

- They have powerful fangs and bites can cause moderate to severe pain, usually short-lived, with occasional non-specific systemic symptoms.
- While initially unpleasant, bites do not appear dangerous to humans, although bites are usually lethal to dogs.



Wolf spider, *Lycosa* spp.



Bird-eating spider ("tarantula")
Selenocosmia stirlingi.

Australian spiders overview: Other spiders

Orb weaving spiders^{8,54}

- These common spiders of the family Araneidae, with many species, build “typical” spider webs in the garden at night.
- People walking into the web and crushing the spider against their body may be bitten, resulting in mild local pain of short duration and a small red lump, lasting about 24 hours.
- These spiders also may hide in clothing left outside overnight, on washing lines.
- The next person to put the clothing on may be bitten!



Garden orb weaver,
Eriophora spp.



Golden orb weaver,
Nephila spp.

Trapdoor spiders^{7,55}

- Includes a number of species of robust, ground dwelling, burrowing mygalomorph spiders, with very large fangs (families Idiopidae; Nemisiidae).
- They are often dug up in gardens.
- Despite the spider's size, bites appear to cause mostly mild pain, and occasionally, severe pain of short duration. There are rare cases of minor non-specific systemic effects.
- These spiders are frequently misidentified as funnel web spiders and therefore are part of the big black spider group (bites by these spiders should be regarded as potential funnel web spider bites and managed accordingly – see page 197).



Trapdoor spider,
Aganippe subtristis.

Photos copyright A/Prof Julian White.